Chula Med J. March - April 2026;70**(2):** 147 - 153 **DOI : 10.56808/2673-060X.**5657

Case report

Sequential presentation of diabetic ketoacidosis, acute ischemic stroke, and ST-elevation in myocardial infarction: a case report

Ichlasul Mahdi Fardhani[a], Putu Aditya Darmawan[b, *], Hammam Arif Shabri[a], Muhammad Isra Rafidin Rayyan[a], Zarrah Yuniar Qolbi Harris[c], Tristi Lukita Wening[d], Azham Purwandhono[a, e]

[a]*Faculty of Medicine, Jember University, Jember, Indonesia*
[b]*Department of Cardiology and Vascular Medicine, Dr. Haryoto Regional Hospital, Lumajang, Indonesia*
[c]*Department of Neurology, Dr. Haryoto Regional Hospital, Lumajang, Indonesia*
[d]*Department of Emergency Medicine, Dr. Haryoto Regional Hospital, Lumajang, Indonesia*
[e]*Department of Neurology, Dr. Soebandi Regional Hospital, Jember, Indonesia*

Abstract

Cardio-cerebral infarction is the simultaneous occurrence of acute ischemic stroke (AIS) and acute myocardial infarction (AMI), and it is a rare and life-threatening emergency. Management thereof is more challenging when it is accompanied by metabolic complications such as diabetic ketoacidosis (DKA). Here, we report a case of a 45-year-old man with hypertension and a history of chronic smoking, who was found unresponsive with right-sided hemiparesis. He was well when last seen 6 hours before arrival. Upon examination, he was hypertensive, tachypneic, had a ketotic breath odor, a Glasgow Coma Scale of 12, and a National Institutes of Health Stroke Scale score of 15. Laboratory results confirmed DKA, with a random blood glucose of 412 mg/dL and metabolic acidosis, and a non-contrast brain computed tomography revealed an acute infarct in the left parietal lobe. Initial management included intravenous fluids, insulin, and clopidogrel. Six hours after admission, he developed sudden chest pain radiating to the jaw with diaphoresis; an electrocardiogram revealed inferior–posterior ST-segment elevation. He was treated with intravenous morphine and dual antiplatelet therapy. Echocardiography on day 2 revealed akinetic left ventricular anterior segments and a reduced ejection fraction (39.0%). This case emphasizes the need for the rapid, multidisciplinary management of concurrent DKA, AIS, and ST-elevation myocardial infarction. Careful timing of the interventions to balance bleeding, thrombolysis, and hemodynamic risks, combined with the coordinated input from neurologists, cardiologists, and endocrinologists, enabled patient stabilization and discharge on day 6 with improved neurological and cardiac outcomes.

Keywords: Brain ischemia, cardio-cerebral infarction, critical care, diabetic ketoacidosis, myocardial infarction.

Cardio-cerebral infarction (CCI) is a rare but life-threatening condition that involves the simultaneous occurrence of acute ischemic stroke (AIS) and acute myocardial infarction (AMI).[1] While AIS and AMI are each critical emergencies, their concurrent occurrence substantially complicates clinical management. CCI is classified into synchronous and metachronous forms, where synchronous involves simultaneous cerebral and coronary infarction and metachronous when one event precedes the other.[2] Although metachronous cases are more frequently reported, the incidence of synchronous CCI remains unclear because of its rarity.[3] Diagnosis involves identifying acute neurological deficits alongside clinical or biochemical evidence of myocardial infarction. Comorbidities such as diabetic ketoacidosis (DKA) may worsen the prognosis, thereby necessitating a multidisciplinary approach involving a neurologist, cardiologist, and endocrinologist.[1] Therefore, the primary objective of this case report is to detail the complex clinical course and management of a patient presenting with DKA and AIS who subsequently developed ST-elevation myocardial infarction

*__Correspondence to__: **Putu Aditya Darmawan,** Department of Cardiology and Vascular Medicine, dr. Haryoto Regional Hospital, Lumajang, Indonesia.
E-mail: putu.aditya.dk@gmail.com
Received: July 15, 2025
Revised: December 15, 2025
Accepted: January 20, 2026

Open Access 2026 Fardhani., published by Faculty of Medicine, Chulalongkorn University. This work is licensed under the Creative Commons Attribution 4.0 International License.

(STEMI) within a short timeframe. This report specifically highlights the diagnostic considerations and therapeutic dilemmas faced due to contraindications as well as resource limitations and the critical role of adaptive multidisciplinary strategies in achieving a favorable patient outcome, as presented by the CARE 2013 guidelines.[4]

Case report

A 45-year-old male presented to the emergency department (ED) with decreased consciousness, which was first noted when he was found unresponsive upon attempts to awaken him. The last time that he was known to be well was approximately 6 hours before admission. Before he was found unresponsive, the patient had initially experienced mild right-sided weakness and subtle speech difficulty, which he had dismissed. Hours before arrival at the ED, his condition had subsequently worsened, progressing to complete right-sided hemiparesis and aphasia. This deterioration continued until the patient lost consciousness and was then found in this state. His wife reported that he was unable to move his right side and could not speak. The patient had a history of uncontrolled hypertension for 3 years and a longstanding smoking habit, with no known history of diabetes mellitus before this admission and no use of glucose-lowering medications.

Upon initial physical examination, the patient presented with a blood pressure of 147/101 mmHg, a pulse rate of 86 beats/min, a respiratory rate of 32 breaths/min, a body temperature of 36.8°C, and a noticeable ketone odor on his breath. Neurologically, the patient had a Glasgow Coma Scale score of E3V4M5, with right-sided motor lateralization, and an initial National Institutes of Health Stroke Scale (NIHSS) score of 15. Immediate investigations included laboratory tests and a non-contrast computed tomography (NCCT) scan of the head, which revealed a hypodense focal lesion in the left parietal lobe **(Figure 1)**. Arterial blood gas analysis revealed metabolic acidosis accompanied by marked hyperglycemia. Detailed laboratory findings are provided in **Table 1.**

Based on the examination results, the patient was initially diagnosed with AIS and DKA. The patient was immediately clinically treated with a 10 L/min O_2 mask, nasogastric tube insertion, and a 0.9% NaCl fluid infusion of 800 cc in 1 h, followed by 3800 cc over 48 h for DKA fluid correction. Insulin was given as a continuous intravenous (IV) drip at a rate of 4 IU/h, with an additional IV bolus of 4 IU administered three times/h. For AIS, the patient received clopidogrel as single antiplatelet therapy (SAPT) that was administered orally with a loading dose of 300 mg, followed by 1 × 75 mg. In addition, 2 × 500 mg of citicoline was injected, and 2 × 500 mg of mecobalamin was given as a neuroprotective agent. Due to leukocytosis, the patient was also given 1 g IV cefotaxime twice daily as an empirical antibiotic. This management was performed simultaneously to treat both conditions. Fibrinolytic therapy with alteplase could not be implemented because the patient did not meet the required criteria. The patient regained consciousness, and a repeat random blood glucose examination revealed a level of 219 mg/dL. The patient was then transferred to regular inpatient care after his condition stabilized.

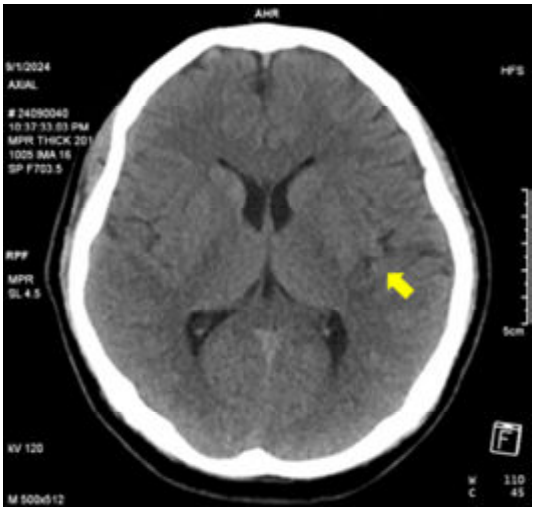

Figure 1. Axial non-contrast head CT scan showing a hypodense lesion in the parietal lobe, suggestive of infarction in the left parietal lobe. CT, computed tomography.

Table 1. Laboratory findings of this patient.

	Day 1	Day 4	Reference range
Complete blood count			
Haemoglobin (g/dL)	14.2	12.2	14.0–18.0
Platelet (10^9/L)	244.0	319.0	150.0–450.0
WBC (10^9/L)	15.2*	14.9*	3.5–10.0
Erythrocytes (cells/uL)	4.2	4.0	4.5–6.5
Basic metabolic panel			
RBG (mg/dL)	412*	NR	< 200
HbA1C (%)	10*	NR	4.0–5.6
BUN (mg/dL)	18.2	14.4	10.0–20.0
Creatinine (mg/dL)	2.1*	1.7*	0.5–1.2
Sodium (mmol/L)	138.0	NR	135.0–146.0
Potassium (mmol/L)	4.5	NR	3.5–5.2
Chloride (mmol/L)	104.0	NR	94.0–111.0
Troponin-I	Positive*	NR	Negative
Urine analysis			
Urine ketone	Positive*		Negative
Arterial blood gas analysis			
pH	7.2*	NR	7.3–7.4
PaO_2 (mmHg)	88.0	NR	80.0–105.0
$PaCO_2$ (mmHg)	31.4*	NR	41.0–51.0
HCO_3 (mmol/L)	17.5*	NR	23.0–28.0
BE (mmol/L)	-8.0*	NR	-2.0–3.0

*Abnormal findings. BE, base excess; BUN, blood urea nitrogen; HCO_3, hydrogencarbonate. $PaCO_2$, partial pressure of carbon dioxide; PaO_2, partial pressure of oxygen; NR, not reported; RBG, random blood glucose; WBC, white blood cell.

Six hours after admission, the patient experienced sudden chest pain radiating to the jaw, accompanied by a cold sweat. Upon examination, the patient was agitated with a blood pressure of 142/92 mmHg, a pulse of 93 beats/min, and a respiratory rate of 24 breaths/min. Electrocardiogram (ECG) examination **(Figure 2)** showed inferior–posterior ST-segment elevation with reciprocal ST depression on V1–V3. One day later, the ECG revealed ST-segment resolution on the inferior lead. Cardiac biomarker evaluation revealed positive troponin I, thus confirming the diagnosis of STEMI. The patient received 2 mg IV of morphine sulfate and dual antiplatelet therapy (DAPT) with aspirin and clopidogrel. Aspirin was administered with a loading dose of 325 mg followed by 80 mg once daily, while clopidogrel was reloaded with 300 mg and continued at 75 mg once daily. The patient was also prescribed oral atorvastatin, starting with a loading dose of 2 × 40 mg, followed by a maintenance dose of 40 mg once daily. In addition, the patient received 2 × 2.5 mg of nitroglycerin as part of the treatment regimen. Percutaneous coronary intervention (PCI) and fibrinolytic therapy for AMI were not performed for this patient, as we did not have access to such facilities, and there were contraindications to fibrinolytic therapy, respectively. The patient was subsequently transferred to the intensive care unit.

On the second day, the patient underwent transthoracic echocardiography, the results of which demonstrated a left ventricular anterior segment akinetic at the basal, mid, and apical levels, with a left ventricular ejection fraction of 39.0%, which is consistent with ischemic heart disease features. The following day, the patient's condition stabilized with only occasional chest pain. Examination of the patient's vital signs revealed a blood pressure of 133/78 mmHg, a pulse rate of 82 beats/min, a respiratory rate of 16 breaths/min, and a temperature of 37.5°C. The neurological status examination showed Broca's aphasia and an NIHSS score of 11. Follow-up laboratory tests performed on day 4 of admission are detailed in **Table 1.** On day 5, after his condition stabilized, the patient was transferred to an inpatient ward. The patient was then observed for 1 day and discharged on day 6 of hospitalization. The clinical course of the disease is summarized in **Figure 3**.

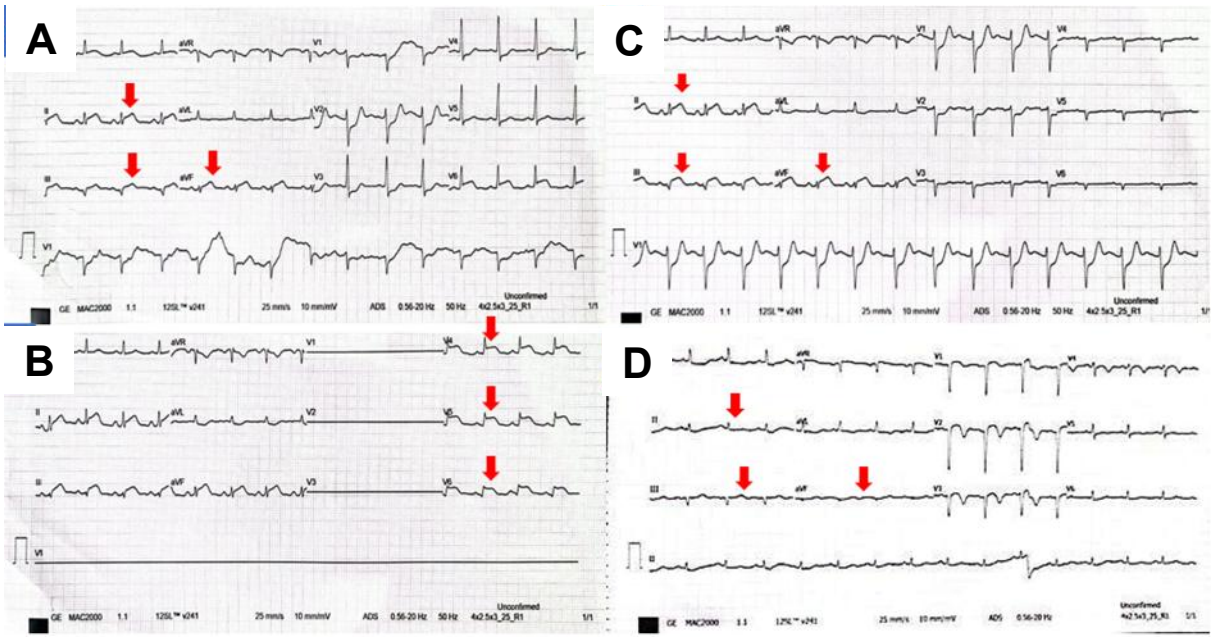

Figure. 2. Serial electrocardiograms. **(A)** and **(B)** inferior and posterior ST-segment elevation consistent with acute myocardial infarction; **(C)** right-sided ECG; **(D)** subsequent ST-segment resolution on follow-up ECG. ECG, electrocardiogram.

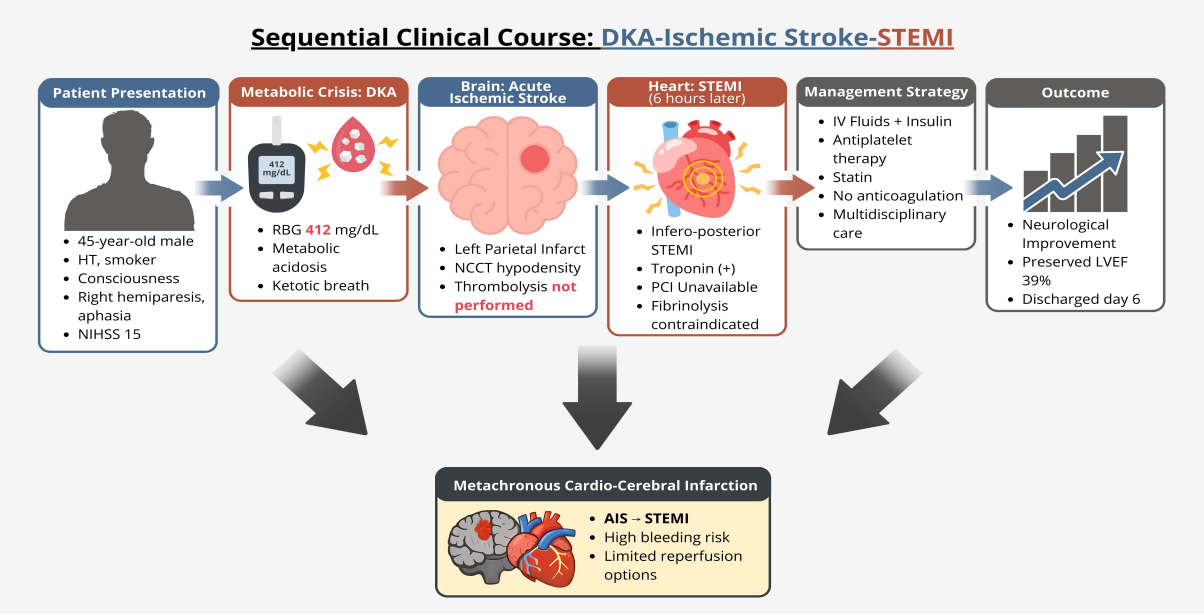

Figure 3. Patient clinical timeline.

Discussion

This case highlights two critical considerations. First, the patient presented with an unknown onset of DKA and AIS, which rendered fibrinolytic therapy contraindicated. According to the American Heart Association (AHA), fibrinolytics are relatively contraindicated when blood glucose levels exceed 400 mg/dL (Class IIb, Level of Evidence C), as seen in the case of this patient with a glucose level of 412 mg/dL. However, this is not an absolute barrier, as insulin has a rapid glucose-lowering effect. The more decisive factor was the uncertain stroke onset, as the patient's last known time of being well was approximately 6 hours prior, thus placing him outside the therapeutic window and constituting an absolute contraindication for thrombolysis (Class III, Level of Evidence A).[5] Early ischemic signs on NCCT, such as hyperdense arteries, loss of gray–white differentiation, parenchymal hypodensity, and mass effect, can aid in estimating the onset.[6] Alshoabi S, *et al.* reported that such hypodensities are more commonly seen at 6–72 h post-stroke onset, which supported the decision to withhold fibrinolytic therapy.[7]

The second clinical event occurred 6 hours later when the patient developed chest pain. ECG examination revealed inferior–posterior ST-segment elevation, and positive troponin I confirmed the diagnosis of STEMI. The sequential occurrence of AIS followed by AMI within a short time frame is characteristic of metachronous CCI.[8] The discrepancy between the ECG findings and echocardiographic wall motion abnormalities may reflect dynamic ischemia, transient reperfusion, or an underlying multivessel coronary artery disease. Additional considerations include coronary anatomy variations (e.g., a wraparound left anterior descending artery), the possibility of multivessel disease or double culprit lesions, and the limitations of bedside echocardiography in resource limited settings, which would precisely localize the culprit vessel without angiography.[9, 10]

The simultaneous occurrence of AIS and AMI, termed CCI, presents a complex therapeutic dilemma. Because of its rarity, no clinical trials or established guidelines have demonstrated a bidirectional relationship between AIS and AMI. However, a large retrospective study (2000–2017) involving 11,622,528 patients with AMI found that 1.6% (183,896 cases) developed AIS within 24 h.[11] The pathophysiology of this critical condition is likely multifactorial, involving mechanisms such as intracardiac thrombus formation secondary to left ventricular systolic dysfunction and catecholamine-induced myocardial injury due to sympathetic surges following cerebral infarction, particularly involving the insular cortex. In this patient, echocardiography revealed akinetic left ventricular anterior segments, which is a risk factor for thrombus formation. [1] As no established guidelines currently exist, therapeutic decisions must rely on case reports and expert consensus. As summarized in **Table 2**,

Table 2. Comparison of previous CCI cases.

Parameter	This case	Lee K, *et al.* 2021	de la Torre C, *et al.* 2024	Grela I, Peterson TR, 2025
Age/sex	45/M	54/M	67/M	51/M
Risk factors	Smoking, diabetes, hypertension	Smoking, diabetes, hypertension	Hyperlipidemia, paroxysmal atrial fibrillation, smoking, and obstructive sleep apnea	Diabetes, hypertension, hyperlipidemia
Initial symptoms	Hemiparesis + decrease of conciousness	Hemiparesis	Chest pain + hemiparesis	Hemiparesis + aphasia
Stroke *vs.* AMI onset	Stroke first; MI after 6 hours	Simultaneous	Simultaneous	Stroke first; MI occurred after thrombectomy
Imaging & ECG findings	• ECG: posterior STEMI • NCCT: left parietal infarct • MRI: no data	• ECG: inferior STEMI • NCCT: Right MCA infarct • MRI: no data	• ECG: anterior STEMI • NCCT: no data • MRI: Right MCA infarct	• ECG: anteroseptal infarct • NCCT: no data • MRI: left MCA infarct
Initial management	Supportive + medical therapy; no PCI (patient refused)	Alteplase + attempted thrombectomy; aborted due to cardiac arrest → ECMO + PCI	Tenecteplase followed by thrombectomy, PCI not performed	Tenecteplase followed mechanical thrombectomy → PCI with aspiration and DES after transfer
Outcome	Good recovery	Death	Good recovery	Good recovery

AF, atrial fibrillation; AMI, acute myocardial infarction; DES, drug-eluting stent; ECG, electrocardiogram; ECMO, extracorporeal membrane oxygenation; MCA, middle cerebral artery; MI, myocardial infarction; MRI, magnetic resonance imaging; NCCT, non-contrast computed tomography; PCI, percutaneous coronary intervention; STEMI, ST-elevation myocardial infarction.

previous reports have described metachronous and simultaneous presentations of CCI, with management strategies ranging from fibrinolysis to mechanical thrombectomy and PCI. In this case, fibrinolytic therapy was contraindicated due to an unknown stroke onset, the presence of DKA, and a recent history of AIS, which is an absolute contraindication for fibrinolysis in STEMI. Although PCI was considered, the patient declined the procedure, thus necessitating a conservative and supportive management approach. While such a strategy is often associated with poorer outcomes, this case achieved clinical stabilization, emphasizing the importance of early recognition and multidisciplinary care. [12–14] Previous studies have demonstrated that timely reperfusion significantly improves prognosis. Chao et al. reported a reduction in all-cause mortality with fibrinolysis among patients with STEMI unable to undergo PCI, and Rodrigo et al. observed increased mortality and adverse events in patients who received no reperfusion therapy. [15,16]

For the management of AIS, aspirin is recommended at an initial dose of 300 mg (Class I, Level A evidence); however, antiplatelet therapy is not a substitute for fibrinolysis or thrombectomy. The antiplatelet regimen choice is guided by stroke severity, which is often assessed using the NIHSS. With an NIHSS score of 15, the patient was initiated on SAPT as per standard recommendations. [5] However, the onset of STEMI within the following 6 h necessitated a second antiplatelet approach, and DAPT was initiated, given the limited reperfusion options available and the need to maintain adequate perfusion. Anticoagulant therapy, though typically indicated for AMI (Class I, Level A evidence), was withheld because of the heightened risk of hemorrhagic transformation. [17] Known risk factors for hemorrhagic transformation include hyperglycemia, an NIHSS score >15, hypertension, previous use of antithrombotic agents, and age ≥ 75 years. [18] Consistent with this, the AHA guidelines advise against the routine early use of anticoagulants in patients with AIS to prevent neurological complications (Class III, Level A evidence). [5] However, to date, information on the risk of hemorrhagic transformation in the context of CCI remains limited. Given the scarcity of high-quality data, clinicians should adopt a personalized approach for patient management, emphasizing fibrinolytic therapy and mechanical revascularization, while carefully evaluating the risks of bleeding and other comorbid conditions. [1]

Conclusion

The management of DKA concurrently with AIS and a subsequent STEMI presents profound diagnostic and therapeutic dilemmas, as illustrated by this case. However, despite substantial limitations, including contraindications to thrombolysis for AIS and STEMI and the unavailability of PCI, a favorable patient outcome was achieved. This was attributable to prompt DKA correction, meticulous individualized antithrombotic therapy balancing ischemic benefits against hemorrhagic risks, and cohesive multidisciplinary care. This report emphasizes the imperative for heightened clinical vigilance for sequential or concurrent vascular events in patients with severe DKA. Furthermore, it reinforces the necessity for adaptive, patient-centered strategies in complex, high-risk scenarios.

Author contributions

IMF, MIRR, and HAS contributed substantially to the concept and design of this study, acquiring the data, reviewing the literature, and its analysis and interpretation. IMF, MIRR, and HAS contributed substantially to acquiring the data. IMF, MIRR, and HAS contributed to drafting the manuscript. AP, TLW, PAK, and ZYQ edited the manuscript critically for important intellectual content. All authors approved the final version submitted for publication and take responsibility for statements made in the published article.

Acknowledgements

The authors would like to express their gratitude to all participants who were involved in this study.

Conflict of interest

All authors have completed and submitted the International Committee of Medical Journal Editors Uniform Disclosure Form for Potential Conflicts of Interest. All authors declare that they have no conflicts of interest.

Data sharing statement

All data generated or analyzed in the present study are included in the published article. Further details are available for non-commercial purposes from the corresponding author upon reasonable request.

ORCID
Ichlasul Mahdi Fardhani https://orcid.org/0000-0003-1538-3318
Putu Aditya Darmawan Kuntadi https://orcid.org/0009-0003-1070-8993
Hammam Arif Shabri https://orcid.org/0009-0005-3049-8924
Muhammad Isra Rafidin Rayyan https://orcid.org/0009-0003-4445-010X
Zarrah Yuniar Qolbi https://orcid.org/0009-0009-6456-9101
Tristi Lukita Wening https://orcid.org/0009-0000-8903-3922
Azham Purwandhono https://orcid.org/0000-0002-2303-5455

References

1. Akinseye OA, Shahreyar M, Heckle MR, Khouzam RN. Simultaneous acute cardio-cerebral infarction: is there a consensus for management? Ann Transl Med 2018;6:7–7.
2. Engel Gonzalez P, Omar W, Patel K V, de Lemos JA, Bavry AA, Koshy TP, et al. Fibrinolytic strategy for ST-segment–elevation myocardial infarction: a contemporary review in context of the COVID-19 pandemic. Circ Cardiovasc Interv 2020;13:e009622.
3. Kim S, Chung H, Lee Y, Yoon BA, Kim DH, Jeong JH, et al. Is the mechanism of synchronous cardiocerebral infarction (CCI) different from that of metachronous CCI? J Neurocritical Care 2023; 16:77–84.
4. Gagnier JJ, Kienle G, Altman DG, Moher D, Sox H, Riley D, et al. The CARE guidelines: consensus-based clinical case reporting guideline development. J Med Case Rep 2013;7:223.
5. Powers WJ, Rabinstein AA, Ackerson T, Adeoye OM, Bambakidis NC, Becker K, et al. Guidelines for the early management of patients with acute ischemic stroke: 2019 update to the 2018 guidelines for the early management of acute ischemic stroke: a guideline for healthcare professionals from the American Heart Association/American Stroke . Stroke 2019;50: e344–418.
6. van Poppel LM, Majoie CBLM, Marquering HA, Emmer BJ. Associations between early ischemic signs on non-contrast CT and time since acute ischemic stroke onset: A scoping review. Eur J Radiol 2022;155:110455.
7. Alshoabi S, Alnajmani R, Shamsuddin M, Gameraddin M. Early signs of middle cerebral artery infarction on multidetector computed tomography: Review of 20 cases. Brain Circ 2019;5:27–31.
8. de Castillo LLC, Diestro JDB, Tuazon CAM, Sy MCC, Añonuevo JC, San Jose MCZ. Cardiocerebral infarction: a single institutional series. J Stroke Cerebrovasc Dis 2021;30:1–8.
9. Tuohinen SS, Rankinen J, Skyttä T, Huhtala H, Virtanen V, Kellokumpu-Lehtinen PL, et al. Associations between ECG changes and echocardiographic findings in patients with acute non-ST elevation myocardial infarction. J Electrocardiol 2018;51:188–94.
10. Schindler TH, Arai AE, Berry C, Sykes R, Nieman K, Kitagawa K, et al. Myocardial blood flow assessment and reporting for ischemic heart disease: Cardiac PET, MR, CT, and echocardiography. JACC Cardiovasc Imaging. JACC Cardiovasc Imaging. 2026;19:378–411.
11. Aggarwal G, Patlolla SH, Aggarwal S, Cheungpasitporn W, Doshi R, Sundaragiri PR, et al. Temporal trends, predictors, and outcomes of acute ischemic stroke in acute myocardial infarction in the United States. J Am Heart Assoc 2021;10:1–18.
12. Lee K, Park W, Seo KD, Kim H. Which one to do first?: a case report of simultaneous acute ischemic stroke and myocardial infarction. J Neurocritical Care 2021;14:109–12.
13. de la Torre C, Wagner JS, Xu J. Concurrent cardio-cerebral infarction - A case report and literature review. The neurohospitalist 2024;14:74–8.
14. Grela I, Peterson TR. Synchronous acute ischemic stroke and acute myocardial infarction: a case report. Cureus 2025;17:e80054.
15. Wu C, Li L, Wang S, Zeng J, Yang J, Xu H, et al. Fibrinolytic therapy use for ST - segment elevation myocardial infarction and long term outcomes in China/ : 2 year results from the China acute myocardial infarction registry. BMC Cardiovasc Disord 2023; 1–10.
16. Gopar-Nieto R, González-Pacheco H, Arias-Mendoza A, Briseño-De-la-cruz JL, Araiza-Garaygordobil D, Sierra-Lara-martínez D, et al. Non-reperfused ST-elevation myocardial infarction: notions from a low-to-middle-income country. Arch Cardiol Mex 2023; 93:4–12.
17. Byrne RA, Rossello X, Coughlan Jj, Barbato E, Berry C, Chieffo A, et al. 2023 ESC guidelines for the management of acute coronary syndromes: developed by the task force on the management of acute coronary syndromes of the European society of cardiology (ESC). Eur Hear J Acute Cardiovasc Care 2024;44: 3720–826.
18. Kovács KB, Bencs V, Hudák L, Oláh L, Csiba L. Hemorrhagic transformation of ischemic strokes. Int J Mol Sci 2023;24:14067.