JMUH
Journal of Medicine and Urban Health

REVIEW ARTICLE

The Minimally Invasive Anterolateral Approach in Supine Position for Primary Total Hip Arthroplasty: Surgical Technique and a Narrative Review of Clinical Outcomes

Pichayut Wattanapreechanon MD[1], Fritz Thorey MD[2]

[1] *Department of Orthopaedics, Faculty of Medicine Vajira Hospital, Navamindradhiraj University, Bangkok 10300, Thailand*

[2] *International Centre for Hip, Knee and Foot Surgery, Sports Traumatology, ATOS Hospital, Heidelberg 69117, Germany*

Corresponding author
Pichayut Wattanapreechanon
pichayut@nmu.ac.th
Received 26 Jan 2026
Revised 19 April 2026
Accepted 28 May 2026
J Med Urban Health e8368
https://doi.org/10.62691/jmuh.2026.8368

ABSTRACT

The anterolateral approach has been widely adopted in total hip arthroplasty (THA), with numerous modifications described since its original introduction. Among these, the minimally invasive anterolateral (MIS-AL) approach, also referred to as the anterior-based muscle-sparing approach, has been developed to minimize soft-tissue damage by preserving the integrity of the gluteus medius muscle. This narrative review describes the surgical technique of the MIS-AL approach for primary THA performed in the supine position and provides a summary of clinical outcomes. When performed in the supine position, the MIS-AL approach offers several advantages beyond its muscle-sparing nature. It does not require a specialized operating table, allows for a simplified operating room setup, facilitates the use of intraoperative fluoroscopy, and enables simultaneous bilateral THA without the need for re-draping. In addition, available evidence suggests that this approach is associated with faster postoperative recovery and a reduced risk of postoperative dislocation, supporting the MIS-AL approach as a reliable and muscle-sparing option for primary THA.

Keywords: anterior-based muscle-sparing approach, anterolateral approach, arthroplasty, hip, total hip arthroplasty

This work is licensed under a Creative Commons Attribution-NonCommercial-NoDerivatives 4.0 International License.

INTRODUCTION

The anterolateral (AL) approach to the hip joint was popularized by Watson-Jones in 1963, when he described femoral neck fracture fixation through the intermuscular interval between the tensor fascia lata (TFL) and the gluteus medius (GM). To facilitate exposure, he recommended incising the anterior fibers of the GM.[1] Since then, numerous modifications of the original approach have been proposed, and it has been widely adopted for total hip arthroplasty (THA). In the mid-2000s, there was growing interest in minimally invasive surgery (MIS) for THA, with the aim of achieving faster postoperative recovery and improved cosmetic outcomes.[2,3] Subsequent discussions broadly categorized MIS-THA into two groups. The first focused on reducing the surgical incision length without altering the technique, whereas the second emphasized modifying the approach to preserve muscle integrity.[4] In 2004, Bertin and Röttinger proposed the AL mini-incision for THA where they use a smaller surgical incision and utilized the "Watson-Jones" interval without detaching the GM from its insertion.[5] More recently, Kelly proposed the term anterior-based muscle-sparing (ABMS) approach to emphasize the minimally invasive nature of the technique and to distinguish it from other AL modifications that involve violating the GM muscle.[6]

The MIS-AL approach can be performed with the patient in either the lateral decubitus position, as originally described by Bertin and Röttinger,[5] or in the supine position. The supine position offers several advantages, including a simplified operating room setup that does not require a specialized table and implant placement accuracy comparable to that achieved in the lateral decubitus position.[7,8] Moreover, the supine position facilitates the use of intraoperative fluoroscopy, enabling more accurate assessment of implant positioning and leg length,[9-11] and is particularly well suited to the application of technology-assisted surgical techniques.[12,13] Additionally, the supine position allows simultaneous bilateral THA to be performed without the need for re-draping. This article focuses on the MIS-AL approach in the supine position, with the aim of providing a detailed description of the surgical technique and a narrative review of the clinical outcomes reported in the literature.

METHODS

A literature search was conducted in PubMed for studies published between 2004 and 2025. The year 2004 was selected as the starting point because Bertin and Röttinger first described the MIS-AL approach in that year. The search terms used were ("total hip arthroplasty " OR "total hip replacement") AND ("anterolateral" OR "anterior-based muscle-sparing" OR "ABMS") AND ("outcome" OR "complication"). Retrieved articles were screened by the first author (PW). Studies were included if they reported clinical outcomes or complications following primary THA performed using the MIS-AL approach.

CONTENT OF REVIEW

Surgical Technique

Patient Position and Draping

The patient is placed in the supine position on a standard operative table. The greater trochanter should be positioned at the hinge of the leg plates, allowing the operative leg to drop into hyperextension and thereby facilitating femoral exposure. A side support is placed at the contralateral ankle to prevent the leg from falling off the table, and a body strap may be applied for additional stabilization. The skin is prepped from just proximal to the anterior superior iliac spine (ASIS) down to proximal thigh area. A sterile custom drape designed for anterior THA is then applied, incorporating a built-in limb stockinette and an incision window (Figure 1).

Figure 1 Patient positioning

https://doi.org/10.62691/jmuh.2026.8368

Surgical Landmark and Incision

A proximal skin incision is made 2–3 fingerbreadths lateral to the ASIS and extended distally along the anterior border of the greater trochanter (Figure 2). Superficial dissection is then carried out, during which small perforating vessels may be encountered and are coagulated using electrocautery. The fascial layers of the TFL and GM are identified, with the thicker, whiter fascia overlying the GM distinguishable from the thinner fascia covering the TFL. A scalpel is used to incise the fascia over the GM in line with the skin incision, typically approximately 0.5 cm lateral to the fascia over the TFL (Figure 3). The interval between the TFL and GM is then bluntly developed using finger dissection, sweeping deeply to elevate the abductor muscles from the underlying joint capsule.

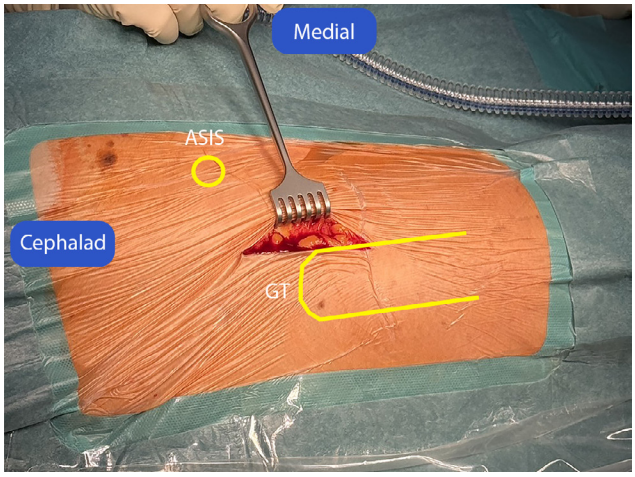

Figure 2 Surgical incision is typically made 2–3 fingerbreadths lateral to the ASIS and extended distally along the anterior border of the greater trochanter.

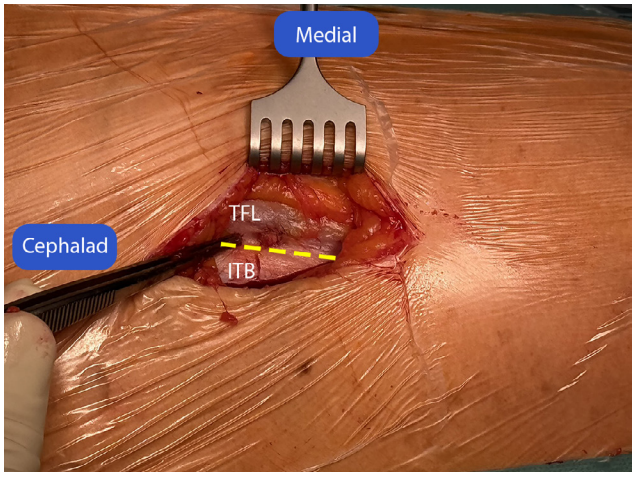

Figure 3 Distinguish the thinner fascial layer over the TFL from the thicker iliotibial band fascia overlying the GM.

Capsular Exposure and Femoral Neck Osteotomy

A curved Hohmann retractor is first placed over the capsule at the superior aspect of the femoral head to retract the abductor muscles. A second retractor is then positioned at the anterior rim of the acetabulum (Figure 4). This retractor placement allows full visualization of the anterior hip capsule, after which either capsulectomy or capsulotomy with subsequent repair may be performed. Given that the benefits of anterior capsular repair following THA, particularly in terms of clinical outcomes and early postoperative hip dislocation rates, remain inconclusive,[14-17] capsulectomy is recommended, especially in cases of limited surgical visualization or during the surgeon's learning-curve phase.

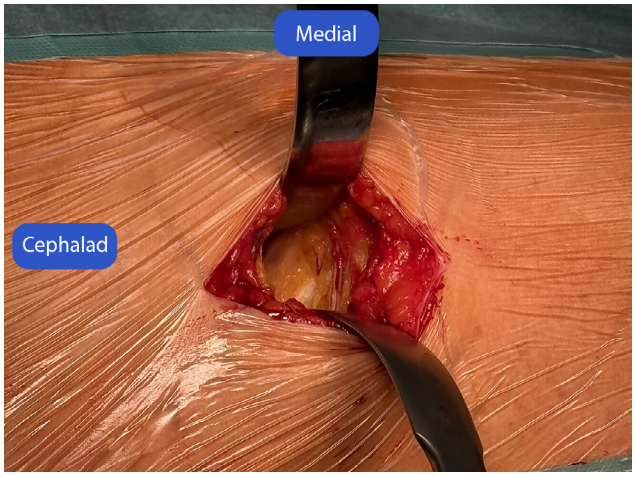

Figure 4 After the interval between the TFL and gluteus medius was developed, the anterior hip capsule was exposed. Either a capsulotomy or capsulectomy can then be performed.

The femoral neck osteotomy may then be performed either after dislocation of the hip or in situ. Dislocation is assessed by placing a bone hook on the medial side of the femoral neck and applying upward traction while an assistant externally rotates and adducts the leg. If dislocation is not possible, a napkin-ring cut of the femoral neck is performed, followed by insertion of a corkscrew into the femoral head for extraction. The residual femoral neck is subsequently assessed and, if necessary, further osteotomized to match the preoperative template and to ensure that it does not impede acetabular preparation.

Soft-tissue release around the proximal femur is then performed to improve acetabular and femoral exposure. With the leg slightly externally rotated by

the assistant, a curved Hohmann retractor is placed just lateral to the greater trochanter to elevate the proximal femur, while another curved Hohmann retractor is positioned around the posteromedial calcar. An inside-out release of the superior capsule from the saddle point is then performed. If additional femoral exposure is required, further soft-tissue release around the posterior aspect of the femoral neck may be performed (Figure 5).

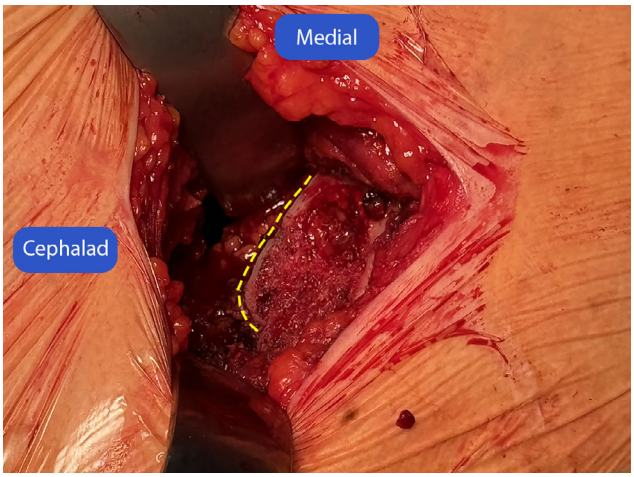

Figure 5 Soft-tissue release around the proximal femur from the superior capsule and extending posteriorly along the osteotomized femoral neck (yellow dashed line).

Acetabular Exposure and Preparation

For acetabular exposure, the assistant maintains the leg in a neutral position. A curved Hohmann retractor is placed on the posterior wall of the acetabulum, and another is positioned on the anterior rim. Care must be taken to ensure that the anterior retractor tip rests securely on bone and is not placed too medially, as this may place adjacent neurovascular structures at risk. The labrum and remaining soft tissues within the cotyloid fossa are then excised.

The acetabular reamer is first introduced manually into the acetabulum, after which an offset reamer handle may be attached once proper seating is achieved (Figure 6). Intraoperative fluoroscopy may be used to confirm the appropriate size and depth of reaming (Figure 7). After reaming is completed, the acetabular component is implanted using an offset cup impactor. The component is positioned to restore the patient's native acetabular anatomy, with the impactor handle serving as an alignment reference relative to the operating table. Repeat intraoperative fluoroscopic assessment during cup implantation is recommended, as pelvic tilt during impaction may influence the final component position.[8] Finally, the selected liner is inserted, and correct engagement within the acetabular shell is confirmed.

Femoral Exposure and Preparation

The leg plates are dropped approximately 30–45° to facilitate hip hyperextension. The assistant positions the operative leg in external rotation, adduction, and hyperextension (Figure 8). Two curved Hohmann retractors are subsequently positioned, one just lateral to the greater trochanter and the other along the posteromedial calcar. If femoral exposure remains inadequate, additional soft-tissue release around the proximal femur should be performed before proceeding with femoral preparation.

Sequential femoral broaching is performed in the standard manner, with an offset broaching handle facilitating the process (Figure 9). After the appropriate broach size is achieved, the trial femoral neck and head are assembled, and the hip is reduced. The leg plates are subsequently returned to the neutral position. Leg length is assessed by comparing the medial malleoli of both legs, and hip stability is evaluated. Intraoperative fluoroscopy is used to confirm the adequacy of femoral implant sizing and leg length restoration (Figure 9). Once satisfactory alignment and stability are confirmed, the trial components are removed, and the final femoral implant is inserted.

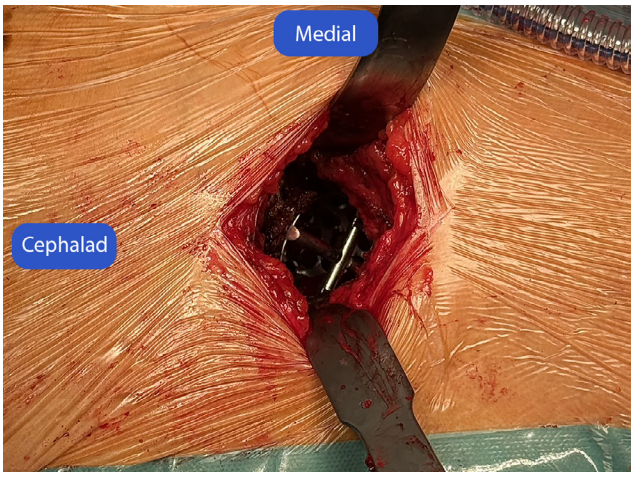

Figure 6 The acetabular reamer basket was placed into the acetabulum and then connected to the offset reamer handle inside.

https://doi.org/10.62691/jmuh.2026.8368

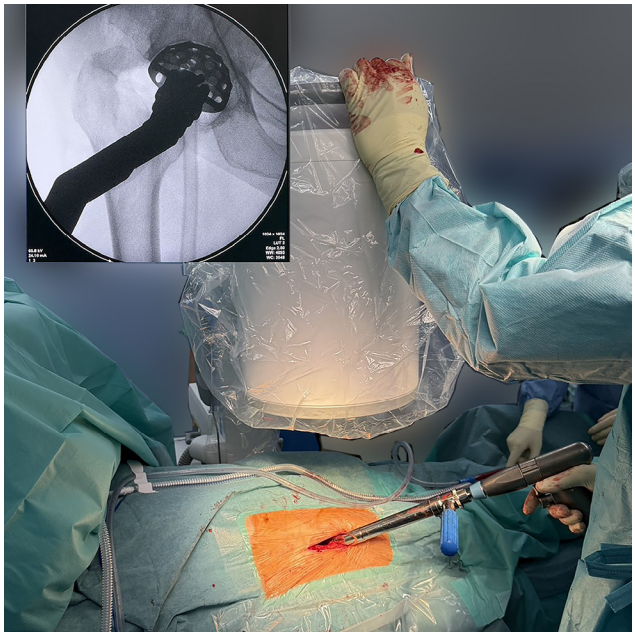

Figure 7 Intraoperative fluoroscopy can be used during acetabular reaming to assess the appropriate size and depth of the reamer.

Figure 8 During femoral preparation, the assistant holds the operative leg in external rotation, adduction, and hyperextension to facilitate exposure.

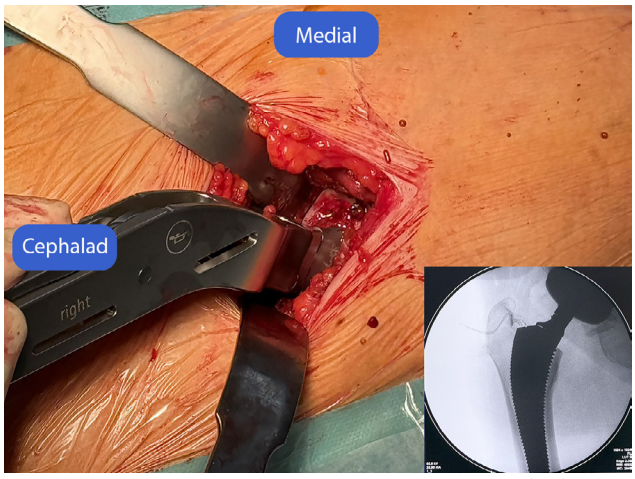

Figure 9 An offset broaching handle facilitates the femoral broaching process.

Closure

After all bleeding points are identified and coagulated, the joint is irrigated with saline and any debris is removed to prevent impingement. The fascia overlying the TFL and GM is repaired with absorbable sutures. The subcutaneous and dermal layers are then closed using the surgeon's preferred technique. Pearls and pitfalls of the surgical technique are described in Table 1.

Table 1 Pearls and pitfalls

Pearl/Pitfall	Recommendations
Specialized instrument	Confirm the availability of specialized instruments preoperatively, as they may not be included in the standard surgical set. These include curved Hohmann retractors, an offset reamer, and offset broaching handles.
Surgical draping	Standard sterile draping of both lower extremities may be used instead of a custom anterior THA drape. Although this requires longer preparation, it provides greater intraoperative control of the legs.
Identification of the TFL-GM interval	Gently scraped the fascia with a scalpel to improve visualization. A perforating vessel is commonly encountered in this interval, and the fascial incision should be made just posterior to it.

https://doi.org/10.62691/jmuh.2026.8368

Table 1 Pearls and pitfalls (continued)

Pearl/Pitfall	Recommendations
Femoral neck osteotomy	Soft-tissue release around the proximal femur at this step may also substantially improve acetabular exposure as well.
Intraoperative femoral fracture	Extend the skin and fascial incision distally until the full extent of the fracture is visualized. Fixation should be selected according to the fracture pattern. Calcar cracks are the most common fracture type and can often be managed successfully with cerclage cable or wire fixation alone.

Abbreviations: GM, gluteus medius; TFL, tensor fascia lata; THA, total hip arthroplasty

Outcomes

The MIS-AL approach for primary THA offers several potential advantages. Most notably, it utilizes the intermuscular interval without intentional detachment of the abductor muscle group, which may facilitate early postoperative recovery. In a randomized controlled trial, Müller et al. compared abductor muscle damage between patients undergoing THA via the MIS-AL approach and those treated with the direct lateral approach. Magnetic resonance imaging (MRI) performed at 12 months postoperatively demonstrated a lower incidence of GM tendon defects (9% vs. 25%) and less fatty atrophy of the anterior portion of the GM muscle (fatty atrophy grade 0.98 ± 1.1 vs. 1.75 ± 1.8) in the MIS-AL group.[18]

In a subsequent prospective cohort study, Müller et al. evaluated gluteus minimus muscle damage following primary THA performed using either the MIS-AL or direct lateral approach. Based on MRI findings at 12 months postoperatively, no significant differences were observed between the two groups in terms of gluteus minimus tendon defects (48% vs. 53%) or severe fatty atrophy of the gluteus minimus muscle (42% vs. 41%).[19] These findings suggest that, although the MIS-AL approach theoretically avoids detachment of the abductor muscles or tendons, some degree of abductor muscle injury may still occur in clinical practice, potentially during capsular exposure or due to retractor compression during acetabular or femoral preparation.

Despite evidence of some abductor muscle changes on MRI following both MIS-AL and direct lateral approaches, Inaba et al. demonstrated a significantly faster recovery of hip abduction strength at six weeks postoperatively in patients who underwent THA using the MIS-AL approach compared with those treated with a mini-incision direct lateral approach ($p < 0.01$). However, no significant differences were observed at 3, 6, or 12 months postoperatively.[20] These results suggest that patients undergoing the MIS-AL approach may be associated with earlier functional recovery compared with conventional approaches.

Consistent with this, Ukai et al. reported that, compared with the posterolateral approach, the MIS-AL approach resulted in earlier cane-assisted ambulation (7.1 ± 2.6 vs. 9.1 ± 3.5 days) and a significantly shorter length of hospital stay (15.5 ± 3.6 vs. 18.6 ± 4.1 days).[21] Similarly, Ostojić et al. reported higher Harris Hip Scores and greater hip muscle strength at three months postoperatively in patients treated with MIS-AL compared with those treated using the posterolateral approach.[22]

In contrast, when compared with the direct anterior approach (DAA), Liu et al. found no significant differences in daily life activities or Japanese Orthopaedic Association hip scores at 2, 6, and 12 weeks postoperatively.[23] Likewise, in a consecutive series of 340 primary THAs performed using either the DAA or MIS-AL approach, Herndon et al. reported no significant differences in opioid consumption, ambulation distance during physical therapy, length of hospital stay (2.0 ± 1.0 vs. 2.1 ± 1.3 days), or rates of discharge to home (87.6% vs. 91.2%).[24] Overall, these findings suggest that MIS-AL approach achieves early recovery outcomes comparable to those of the DAA, which also minimizes muscle injury by utilizing an internervous plane.

Nevertheless, most of the available studies were not randomized controlled trials, and considerable heterogeneity was present in the outcome measures used across studies. Therefore, further studies with more robust designs, ideally incorporating contemporary enhanced recovery after surgery protocols, are warranted.

Another advantage of the AL approach is that it is considered an anterior-based approach, as the hip capsule is opened from the anterior aspect of the joint, which may ultimately reduce dislocation rates after THA. An observational study by Sheth et al. analyzed data from 42,438 primary THAs recorded in

https://doi.org/10.62691/jmuh.2026.8368

the Kaiser Permanente Total Joint Replacement Registry, comparing septic revisions, aseptic revisions, and dislocations across different surgical approaches. They found that both the AL approach (hazard ratio (HR) 0.29; 95% confidence interval (CI), 0.13–0.63; p = 0.002) and the DAA (HR 0.44; 95% CI, 0.22–0.87; p = 0.017) were associated with lower dislocation rates compared with the posterior approach, while the risks of septic and aseptic revision did not differ significantly among the approaches.[25] Although the study included a large number of patients and was based on data from a robust registry, residual confounding factors related to dislocation, such as surgeon experience and postoperative rehabilitation protocols, could not be fully controlled.

More recently, Clesham et al. conducted a meta-analysis restricted to level I evidence comparing minimally invasive intermuscular approaches (MIS-AL and DAA) with conventional approaches. They found no significant difference in dislocation rates (risk ratio 1.00; 95% CI, 0.99–1.01; p = 0.760). Furthermore, there were no significant differences between minimally invasive and conventional approaches for other clinically relevant outcomes, including all-cause revision, aseptic revision, infection, and periprosthetic fracture.[26] However, among the 11 studies included in the meta-analysis, only 2 compared minimally invasive intermuscular approaches with the posterolateral approach, which has consistently been reported to have a higher dislocation rate. The remaining studies used the direct lateral approach as the comparator, which also involves opening the hip capsule from the anterior aspect.

The MIS-AL approach is not without complications, with reported overall complication rates ranging from 1.18% to 5.6% in the literature.[23,27-29] The most frequently reported surgical complications include intraoperative femoral fracture and nerve injury. Intraoperative femoral fractures have been reported in 0.01% to 4.1% of primary THA cases performed using the MIS-AL approach.[11,23,28-31] Van Roekel et al. reported intraoperative femoral fractures in 6 of 507 THAs, most of which were calcar cracks that were successfully managed with cerclage cables.[30] Similarly, Herndon et al. identified intraoperative fractures in 28 of 684 THAs. Across these studies, the calcar was the most commonly involved fracture site, followed by the greater trochanter, and all fractures were treated intraoperatively using cerclage cables or greater trochanteric plates. These authors also identified several risk factors for intraoperative femoral fracture, including advance age, female sex, a larger Dorr ratio, and the use of uncemented tapered-wedge or meta-diaphyseal–fitting femoral stems.[31]

To mitigate this risk, particular care should be taken during femoral preparation, as fractures most commonly occur during broaching and final stem insertion. These steps require forced hyperextension, external rotation, and adduction of the hip; therefore, adequate soft-tissue release around the proximal femur is recommended prior to femoral preparation. In high-risk patients, the use of a cemented or collared femoral stem may be advisable to further reduce the risk of fracture.

Nerve injury has been reported in 0% to 0.6% of cases, with the femoral nerve being the most commonly affected.[11,23,28,32] Such injuries may occur during placement of the anterior acetabular retractor. To minimize this risk, the retractor tip should be securely positioned on the bony surface of the anterior acetabular rim, and excessive traction should be avoided during acetabular preparation. Nevertheless, femoral nerve palsy following the MIS-AL approach is rare, and available evidence suggests that it is often self-limiting.[33] In a study by Fleischman et al., after a mean follow-up of 33.3 months, 75% of patients who developed femoral nerve palsy following THA experienced complete resolution of motor weakness. The remaining patients had only mild residual motor weakness that did not require the use of an assistive walking device, and all patients demonstrated improvement in sensory symptoms.[32]

When comparing rates of lateral femoral cutaneous nerve (LFCN) injury, the DAA is associated with a higher incidence than the MIS-AL approach. This difference is likely attributable to the anatomical course of the nerve, which traverses the typical surgical incision used in the DAA, whereas the more lateralized incision of the MIS-AL approach may reduce the risk of LFCN injury. In a randomized controlled trial, Takada et al. compared 60 patients undergoing primary THA using either the DAA or MIS-AL approach and reported that 23.3% of patients in the DAA group experienced LFCN-related symptoms, whereas no such symptoms were observed in the MIS-AL group. Notably, all reported symptoms resolved within one year postoperatively.[34]

Nevertheless, the reported incidence of LFCN injury following the DAA varies widely in the literature and has been reported to be as high as 81%, as described by Goulding et al.[35] Although most studies suggest that LFCN injury has minimal impact on overall functional outcomes, persistent sensory symptoms have been documented. Patton et al. reported residual neuropathic symptoms in 16% of patients at a mean follow-up of 3.9 years after DAA THA.[36] Similarly, Gala et al. found that 73% of patients continued to experience symptoms of LFCN neuropraxia at a mean follow-up of 5.5 years following DAA THA.[37] Despite the persistence of sensory symptoms, both studies demonstrated no significant differences in hip functional scores between patients with and without LFCN injury.

Complications occur most frequently during the initial learning curve when transitioning to the MIS-AL approach. Reichert et al. demonstrated that after the first 60 primary THA cases performed using the MIS-AL approach, operative time, leg length discrepancy, and complication rates decreased significantly.[38] However, this learning curve can be shortened if the surgeon already has high-volume experience with THA prior to transition. Kagan et al. reported no differences in operative time, blood loss, or immediate postoperative complications for a senior surgeon during his transition from the posterior approach to the MIS-AL approach.[39] In a similar study, Inui et al. found that high-volume surgeons experienced significantly fewer perioperative complications when transitioning to the MIS-AL approach compared with moderate- and low-volume surgeons.[40] For less-experienced surgeons, several authors have recommended careful patient selection during the learning phase, specifically avoiding obese, highly muscular, or osteoporotic patients, as these factors may increase the risk of perioperative complications.[41]

Urban Healthcare Relevance

The global demand for THA has risen substantially. Across analyzed national registries, THA incidence increased by 130% to 210% between 2010 and 2023. Further growth is expected through 2050, with projected increases in THA volume ranging from 121% to more than 200% across countries.[42] This increasing demand may impose a greater burden on high-volume urban centers, where population density and surgical case volume are typically higher. In this context, the choice of surgical approach for THA may be relevant to urban healthcare delivery, particularly when operating room efficiency is a priority.

The MIS-AL approach in the supine position offers straightforward patient setup without the need for a specialized operating table, which may be advantageous in resource-variable environments. In addition, this position facilitates the use of intraoperative fluoroscopy and may improve surgical workflow efficiency. Moreover, the MIS-AL approach may support earlier postoperative recovery and shorter hospitalization. This may reduce resource utilization, including nursing workload and inpatient costs, while potentially improving patient turnover and overall hospital efficiency.

CONCLUSION

The MIS-AL approach represents a viable anterior-based technique for primary THA. Performed in the supine position, it allows for straightforward surgical setup and facilitates accurate implant positioning through the use of intraoperative fluoroscopy. Accumulating evidence suggests that this approach achieves consistent clinical outcomes, characterized by accelerated postoperative rehabilitation and functional results comparable to the DAA, and has shown promising results with respect to dislocation risk compared with conventional direct lateral or posterolateral approaches. However, the incidence of nerve injury, especially LFCN injury, is considerably lower with the MIS-AL approach than with the DAA. Nonetheless, meticulous attention to surgical detail and careful patient selection are essential to minimize complications during the learning curve.

Conflict of Interest

The authors have no conflict of interests to declare that are relevant to the content of this article.

Acknowledgments

Generative AI was used solely to assist with English language editing. All content was reviewed and approved by the authors.

Author Contributions

Conceptualization: P.W., F.T.;

Data curation: –

Formal analysis: –

Funding acquisition: –

Investigation: –

https://doi.org/10.62691/jmuh.2026.8368

Methodology: P.W.

Project administration: P.W.

Resources: F.T.

Software: –

Supervision: F.T.

Validation: P.W., F.T.

Visualization: P.W.

Writing – original draft preparation: P.W.

Writing – review & editing: P.W., F.T.

REFERENCES

1. Watson-Jones R. Fractures of the neck of the femur. Br J Surg 1936;23(92):787-808. PUBMED | CROSSREF
2. Sculco TP. Minimally invasive total hip arthroplasty: in the affirmative. J Arthroplasty 2004;19(4):78-80. PUBMED | CROSSREF
3. Berry DJ. "Minimally invasive" total hip arthroplasty. J Bone Joint Surg Am 2005;87(4):699-700. PUBMED | CROSSREF
4. Röttinger H. The idea of "minimally invasive solution" total hip arthroplasty: history and perspective behind the modernization of surgery through the watson-jones muscle interval. In: Geller JA, McGrory BJ, editors. The anterior-based muscle-sparing approach to Total Hip Arthroplasty. Cham: Springer International Publishing; 2022. p. 1-13.
5. Bertin KC, Röttinger H. Anterolateral mini-incision hip replacement surgery: a modified Watson-Jones approach. Clin Orthop Relat Res 2004;(429):248-55. PUBMED | CROSSREF
6. Lepri AC, Villano M, Matassi F, Carulli C, Innocenti M, Civinini R. "Anterolateral" approach to the hip: a systematic review of the correct definition of terms. Hip Int 2020;30(2 Suppl):13-9. PUBMED | CROSSREF
7. Takada R, Jinno T, Miyatake K, Hirao M, Yagishita K, Yoshii T, et al. Supine versus lateral position for accurate positioning of acetabular cup in total hip arthroplasty using the modified Watson-Jones approach: a randomized single-blind controlled trial. Orthop Traumatol Surg Res 2019;105(5):915-22. PUBMED | CROSSREF
8. Kishimura Y, Minoda Y, Mizokawa S, Sugama R, Ohta Y, Nakamura H. Cup alignment in total hip arthroplasty using the muscle-sparing modified Watson-Jones approach-comparison between lateral and supine positions. Int Orthop 2019;43(11):2477-83. PUBMED | CROSSREF
9. Viglietta E, Fenucci S, Iorio R, Parisien A, Grammatopoulos G, Kim PR, et al. "Intra-operative assessment of leg length discrepancy with anterior approach total hip replacement: a comparison between standard table, position table with and without intra-operative radiographs". Int Orthop 2025;49(5):1065-71. PUBMED | CROSSREF
10. Blum CL, Luzzi AJ, Frederick JS, Cooper HJ, Shah RP, Tatka J, et al. Intraoperative Fluoroscopy Decreases Magnitude and Incidence of Leg-Length Discrepancy Following Total Hip Arthroplasty. Arthroplast Today 2024;30:101492. PUBMED | CROSSREF
11. Civinini R, Cozzi Lepri A, Carulli C, Matassi F, Villano M, Innocenti M. The anterior-based muscle-sparing approach to the hip: the "other" anterior approach to the hip. Int Orthop 2019;43(1):47-53. PUBMED | CROSSREF
12. Tamaki Y, Goto T, Wada K, Omichi Y, Hamada D, Sairyo K. Robotic arm-assisted total hip arthroplasty via a minimally invasive anterolateral approach in the supine position improves the precision of cup placement in patients with developmental dysplasia of the hip. J Orthop Sci 2024;29(2):559-65. PUBMED | CROSSREF
13. Tachibana T, Katagiri H, Ogawa T, Koyano G, Jinno T. Enhancing the accuracy of cup placement in total hip arthroplasty using CT-based navigation by a trainee surgeon: a retrospective cohort study. BMC Musculoskelet Disord 2025;26(1):262. PUBMED | CROSSREF
14. Schwartz AM, Goel RK, Sweeney AP, Bradbury TL Jr. Capsular management in direct anterior total hip arthroplasty: a randomized, single-blind, controlled trial. J Arthroplasty 2021;36(8):2836-42. PUBMED | CROSSREF
15. Vandeputte FJ, Vanbiervliet J, Sarac C, Driesen R, Corten K. Capsular resection versus capsular repair in direct anterior approach for total hip arthroplasty: a randomized controlled trial. Bone Joint J 2021;103-B(2):321-8. BJJ-2020-0529.R2. PUBMED | CROSSREF
16. Lu Y, Wu Z, Tang X, Gu M, Hou B. Effect of articular capsule repair on postoperative dislocation after primary total hip replacement by the anterolateral approach. J Int Med Res 2019;47(10):4787-97. PUBMED | CROSSREF
17. Yano S, Hagiwara S, Iida S, Nakamura J, Kawarai Y, Ohtori S. Effects of anterior capsule repair during total hip arthroplasty using the anterolateral approach in the supine position. J Joint Surg Res 2023;1(1):163-7. CROSSREF
18. Müller M, Tohtz S, Springer I, Dewey M, Perka C. Randomized controlled trial of abductor muscle damage in relation to the surgical approach for primary total hip replacement: minimally invasive anterolateral versus modified direct lateral approach. Arch Orthop Trauma Surg 2011;131(2):179-89. PUBMED | CROSSREF
19. Müller M, Tohtz S, Winkler T, Dewey M, Springer I, Perka C. MRI findings of gluteus minimus muscle damage in primary total hip arthroplasty and the influence on clinical outcome. Arch Orthop Trauma Surg 2010;130(7):927-35. PUBMED | CROSSREF
20. Inaba Y, Kobayashi N, Yukizawa Y, Ishida T, Iwamoto N, Saito T. Little clinical advantage of modified Watson-Jones approach over modified mini-incision direct lateral approach in primary total hip arthroplasty. J Arthroplasty 2011;26(7):1117-22. PUBMED | CROSSREF
21. Ukai T, Ebihara G, Watanabe M. Comparison of short-term outcomes of anterolateral supine approach and posterolateral approach for primary total hip arthroplasty: a retrospective study. J Orthop Traumatol 2021;22(1):6. PUBMED | CROSSREF
22. Ostojić M, Kordić D, Moro G, Ostojić Z. Anterolateral minimally invasive hip approach offered faster rehabilitation with lower complication rates compared to the minimally invasive posterior hip approach—a University clinic case control study of 120 cases. Arch Orthop Trauma Surg 2022;142(5):747-54. PUBMED | CROSSREF

23. Liu H, Yin L, Li J, Liu S, Tao Q, Xu J. Minimally invasive anterolateral approach versus direct anterior approach total hip arthroplasty in the supine position: a prospective study based on early postoperative outcomes. J Orthop Surg Res 2022;17(1):230. PUBMED | CROSSREF
24. Herndon CL, Drummond N, Sarpong NO, Cooper HJ, Shah RP, Geller JA. Direct anterior versus mini-anterolateral approach for primary total hip arthroplasty: early postoperative outcomes and complications. Arthroplast Today 2020;6(2):257-61. PUBMED | CROSSREF
25. Sheth D, Cafri G, Inacio MC, Paxton EW, Namba RS. Anterior and anterolateral approaches for THA are associated with lower dislocation risk without higher revision risk. Clin Orthop Relat Res 2015;473(11):3401-8. PUBMED | CROSSREF
26. Clesham K, Sheridan GA, Greidanus NV, Masri BA, Garbuz DS, Duncan CP, et al. Minimally invasive intermuscular approaches versus conventional approaches in total hip arthroplasty: a systematic review and meta-analysis. J Arthroplasty 2022;37(8):1658-66. PUBMED | CROSSREF
27. Kahn TL, Frandsen JJ, Blackburn BE, Anderson LA, Pelt CE, Gililland JM, et al. Anterior-based approaches to total hip arthroplasty: beyond the learning curve. J Arthroplasty 2022;37(7):S552-S5. PUBMED | CROSSREF
28. Pan T, Mehta A, Mason MW. Outcomes of the supine anterior-based muscle-sparing approach for primary and revision hip arthroplasty. J Am Acad Orthop Surg Glob Res Rev 2022;6(2). PUBMED | CROSSREF
29. Rana AJ, Sturgeon CM, McGrory BJ, Frazier MV, Babikian GM. The ABLE anterior-based muscle-sparing approach: a safe and effective option for total hip arthroplasty. Arthroplast Today 2022;16:264-9.e1. PUBMED | CROSSREF
30. Van Roekel N, Lutnick E, Pavlesen S, Henry M, Haider MN, Phillips M. Perioperative femur fractures in muscle sparing anterolateral - modified Watson-Jones approach to primary total hip arthroplasty: a retrospective cohort study. J Clin Orthop Trauma 2024;59:102828. PUBMED | CROSSREF
31. Herndon CL, Nowell JA, Sarpong NO, Cooper HJ, Shah RP, Geller JA. Risk factors for periprosthetic femur fracture and influence of femoral fixation using the mini-anterolateral approach in primary total hip arthroplasty. J Arthroplasty 2020;35(3):774-8. PUBMED | CROSSREF
32. Fleischman AN, Rothman RH, Parvizi J. Femoral nerve palsy following total hip arthroplasty: incidence and course of recovery. J Arthroplasty 2018;33(4):1194-9. PUBMED | CROSSREF
33. Vajapey SP, Morris J, Lynch D, Spitzer A, Li M, Glassman AH. Nerve injuries with the direct anterior approach to total hip arthroplasty. JBJS Rev 2020;8(2):e0109. PUBMED | CROSSREF
34. Takada R, Jinno T, Miyatake K, Hirao M, Kimura A, Koga D, et al. Direct anterior versus anterolateral approach in one-stage supine total hip arthroplasty. Focused on nerve injury: a prospective, randomized, controlled trial. J Orthop Sci 2018;23(5):783-7. PUBMED | CROSSREF
35. Goulding K, Beaulé PE, Kim PR, Fazekas A. Incidence of lateral femoral cutaneous nerve neuropraxia after anterior approach hip arthroplasty. Clin Orthop Relat Res 2010;468(9):2397-404. PUBMED | CROSSREF
36. Patton RS, Runner RP, Lyons RJ, Bradbury TL. Clinical outcomes of patients with lateral femoral cutaneous nerve injury after direct anterior total hip arthroplasty. J Arthroplasty 2018;33(9):2919-26.e1. PUBMED | CROSSREF
37. Gala L, Kim PR, Beaulé PE. Natural history of lateral femoral cutaneous nerve neuropraxia after anterior approach total hip arthroplasty. Hip Int 2019;29(2):161-5. PUBMED | CROSSREF
38. Reichert JC, Wassilew GI, von Rottkay E, Noeth U. Compared learning curves of the direct anterior and anterolateral approach for minimally invasive hip replacement. Orthop Rev (Pavia) 2022;14(3):37500. PUBMED | CROSSREF
39. Kagan RP, Greber EM, Richards SM, Erickson JA, Anderson MB, Peters CL. Advantages of an anterior-based muscle-sparing approach in transitioning from a posterior approach for total hip arthroplasty: minimizing the learning curve. J Arthroplasty 2019;34(12):2962-7. PUBMED | CROSSREF
40. Inui H, Nakasone I, Kanazawa T, Yamashita T, Tanuma Y, Saita K. Learning curve of minimally invasive anterolateral approach in supine position for total hip arthroplasty. J Joint Surg Res 2024;2(2):31-4. CROSSREF
41. Laffosse JM, Chiron P, Accadbled F, Molinier F, Tricoire JL, Puget J. Learning curve for a modified Watson-Jones minimally invasive approach in primary total hip replacement: analysis of complications and early results versus the standard-incision posterior approach. Acta Orthop Belg 2006;72(6):693-701.
42. Stubnya BG, Schulz M, Váncsa S, Szilágyi GS, Szatmári A, Bejek Z. Global trends in joint arthroplasty: a systematic review and future projections. J Clin Med 2025;14(22). PUBMED | CROSSREF